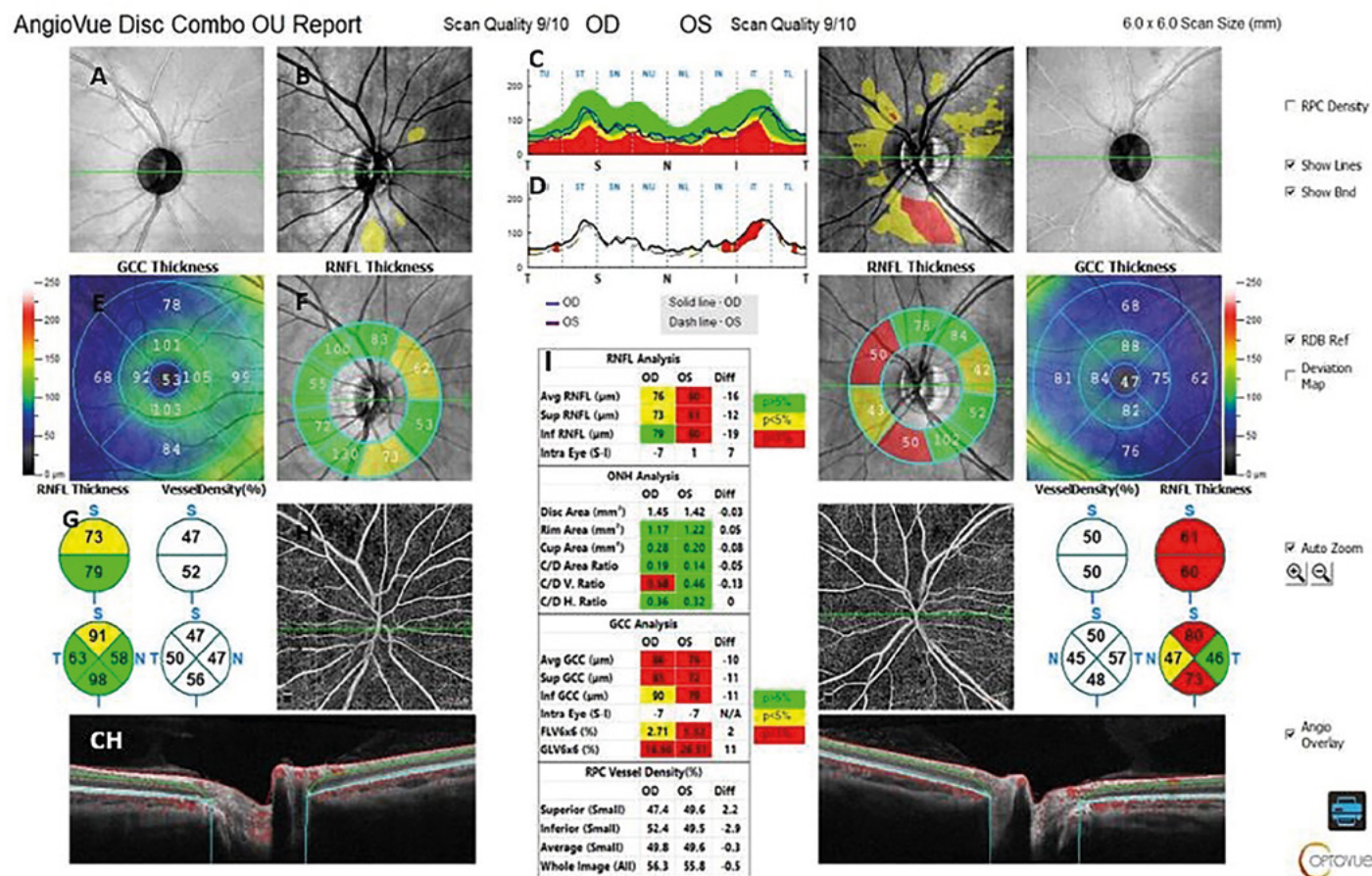


Obř. 5. Výstupný protokol OCT-A zrakového nervu u 40-ročnej pacientky vpravo s MS-NON a vľavo MS-ON. Hore zľava: A) SLO obraz papily a okolia, B) farebná mapa hrúbky RNFL v peripapilárnej oblasti, C) lineárny graf hrúbky RNFL v meranej oblasti, D) lineárny graf porovnávajúci stranový rozdiel hrúbky RNFL z oboch očí, E) farebná mapa hrúbky buniek gangliového komplexu (GCC), F) peripapilárna hrúbka RNFL, G) kruhový segmentovaný graf hrúbky RNFL a denzity ciev, H) OCT-A RPC, CH) lineárny transpapilárny B-sken s vyznačenou cievnu registráciou (červená), I) tabuľka s parametrami z analýzy RNFL, ONH, GCC, RPC denzity ciev (archív Očnej kliniky UPJŠ LF a UNLP Košice)



LITERATÚRA

- Aly L, Noll Ch, Wicklein R, et al. Dynamics of Retinal Vessel Loss After Acute Optic Neuritis in Patients With Relapsing Multiple Sclerosis. *Neurology-Neuroimmunology Neuroinflammation*. 2022;9:3. doi: 10.1212/NXI.0000000000001159.
- Besharse J, Bok D. *The retina and its disorders*. Boston: Academic Press. c2011. ISBN 9780123821980.
- Bulut M, Kurtulus F, Goyozkaya O, et al. Evaluation of optical coherence tomography angiographic findings in Alzheimer's type dementia. *British Journal of Ophthalmology*. 2018;102(2):233-237. doi: 10.1136/bjophthalmol-2017-310476.
- Campbell JP, Zhang M, Hwang TS, et al. Detailed vascular anatomy of the human retina by projection-resolved optical coherence tomography angiography. *Sci Rep*. 2017;7:42201. doi.org/10.1038/srep42201.
- Coscas F, Sellam A, Glacet-Bernard A, et al. Normative data for vascular density in superficial and deep capillary plexuses of healthy adults assessed by optical coherence tomography angiography. *Investigative ophthalmology & visual science*. 2016;57(9):OCT211-OCT223. doi: 10.1167/iovs.15-18793.
- D'haeseleer M, Hostenbach S, Peeters I, et al. Cerebral hypoperfusion: a new pathophysiologic concept in multiple sclerosis? *Journal of Cerebral Blood Flow & Metabolism*. 2015;35(9):1406-1410. doi: 10.1038/jcbfm.2015.131.
- Feigin VL, Abajobir AA, Abate KH, et al. Global, regional, and national burden of neurological disorders during 1990–2015: a systematic analysis for the Global Burden of Disease Study 2015. *The Lancet Neurology*. 2017;16(11):877-897. doi.org/10.1016/S1474-4422(17)30299-5.
- Feucht N, Maier M, Lepenietter G, et al. Optical coherence tomography angiography indicates associations of the retinal vascular network and disease activity in multiple sclerosis. *Multiple Sclerosis Journal*. 2019;25(2):224-234. doi.org/10.1177/1352458517750009.
- Frank RN, Turczyn T, Das A. Pericyte coverage of retinal and cerebral capillaries. *Investigative ophthalmology & visual science*. 1990;31(6):999-1007.
- Hormel T, Hwang TS, Bailey ST, et al. Artificial intelligence in OCT angiography. *Progress in Retinal and Eye Research*. 2021;85:100965. doi.org/10.1016/j.preteyeres.2021.100965.
- Higashiyama T, Nishida Y, Ohji M. Optical coherence tomography angiography in eyes with good visual acuity recovery after treatment for optic neuritis. *PLoS One*. 2017;12(2):e0172168. doi.org/10.1371/journal.pone.0172168.
- Jiang H, Delgado S, Tan J, et al. Impaired retinal microcirculation in multiple sclerosis. *Multiple Sclerosis Journal*. 2016;22(14):1812-1820. doi.org/10.1177/1352458516631035.
- Jiang H, Gameiro GR, Liu Y, et al. Visual function and disability are associated with increased retinal volumetric vessel density in patients with multiple sclerosis. *American journal of ophthalmology*. 2020;213:34-45. doi.org/10.1016/j.ajo.2019.12.021.
- Kaur C, Foulds WS, Ling EA. Blood-retinal barrier in hypoxic ischaemic conditions: basic concepts, clinical features and management. *Progress in retinal and eye research*. 2008;27(6):622-647. doi.org/10.1016/j.preteyeres.2008.09.003.
- Kleerekooper I, Houston S, Dubis AM, et al. Optical coherence tomography angiography (OCTA) in multiple sclerosis and neuromyelitis optica spectrum disorder. *Frontiers in Neurology*. 2020;11:604049. doi.org/10.3389/fneur.2020.604049.1a
- Kleerekooper I, Petzold A, Trip SA. Anterior visual system imaging to investigate energy failure in multiple sclerosis. *Brain*. 2020;143(7):1999-2008. doi.org/10.1093/brain/awaa049.1b
- Kwamong WR, Ye H, Peng C, et al. Retinal microvascular impairment in the early stages of Parkinson's disease. *Investigative ophthalmology & visual science*. 2018;59(10):4115-4122. doi.org/10.1167/iovs.17-23230.
- Lanzillo R, Moccia M, Criscuolo C, et al. Optical coherence tomography angiography detects retinal vascular alterations in different phases of multiple sclerosis. *Multiple Sclerosis Journal*. 2019;25(2):300-301. doi.org/10.1177/1352458518768060.
- Lee GI, Park KA, Oh SY, et al. Differential patterns of parafoveal and peripapillary vessel density in multiple sclerosis and neuromyelitis optica spectrum disorder. *Multiple Sclerosis and Related Disorders*. 2021;49:102780. doi.org/10.1016/j.msard.2021.102780.
- Li Y, Choi WJ, Wei W, et al. Aging-associated changes in cerebral vasculature and blood flow as determined by quantitative optical coherence tomography angiography. *Neurobiology of aging*. 2018;70:148-159. doi.org/10.1016/j.neurobiolaging.2018.06.017.
- Martin AR, Bailie JR, Robson T, et al. Retinal pericytes control expression of nitric oxide synthase and endothelin-1 in microvascular endothelial cells. *Microvascular research*. 2000;59(1):131-139. doi.org/10.1006/mvre.1999.2208.